

Post Craniotomy Blindness due to Optic Neuropathy: Case Report and Review of Literature

Fawaz Eljili^{1*}, Hytham Hussein, MD², Mohammed Mustafa³, Sanna Taha⁴ and Shahd Altayeb⁵

¹Registrar of Neurosurgery, MRCS, MSc (Molecular Medicine), MPH, National centre for Neurological Sciences (NCNS), Khartoum, Sudan.

²Neurosurgery and Endovascular surgery, Neurospine centre, Ribat university hospital, Khartoum, Sudan.

³Registrar of neurosurgery, Neurospine centre, Ribat university hospital, Khartoum, Sudan.

⁴Registrar of neurosurgery, Neurospine centre, Ribat university hospital, Khartoum, Sudan.

⁵Registrar of neurosurgery, Neurospine centre, Ribat university hospital, Khartoum, Sudan.

*Corresponding Author: Dr. Fawaz Eljili, Registrar of Neurosurgery, MRCS, MSc (Molecular Medicine), MPH, National centre for Neurological Sciences (NCNS), Khartoum, Sudan.

Received: July 25, 2022 Published: August 10, 2022

Abstract

Background: Post craniotomy ischemic optic neuropathy is considered a type of broad group named as Postoperative vision loss (POVL). Ischemic optic neuropathy is the most important and common diagnosis for POVL. Most revised literature mentioned ischemic optic neuropathy occurred after spine not cranial.

Discussion: Post craniotomy blindness is not common complication in neurosurgery and is considered catastrophic. Incidence, pathogenesis and risk factors is not fully known. our case is a scenario of post-craniotomy blindness in supine position seen as delayed complication.

Conclusion: Ischemic optic neuropathy is not a common complication and still poorly understood with risk factors considered speculative. its treatment is not known, and so increased understanding should help to prevent that ophthalmological exam and consultation in addition to the medico-legal aspect should be considered for high risk patients.

Keywords: Optic Neuropathy, Postoperative vision loss (POVL), Post Craniotomy

Introduction

Post craniotomy ischemic optic neuropathy is considered a type of broad group named as Postoperative vision loss (POVL). It includes many syndromes, central retina artery occlusion, cortical blindness, ischemic optic neuropathy and rarely otherwise classified blindness(1). Central retina artery occlusion and cortical blindness are caused by painless strokes, primarily embolic in nature.

Ischemic optic neuropathy is the most important and common diagnosis for POVL followed by central retinal artery occlusion. It is an acute ischemic disorder of the optic nerve and has two different forms. Anterior ischemic optic neuropathy (AION) affects the anterior portion of the optic nerve in which it enters the ocular globe and posterior ischemic optic neuropathy (PION) involves the intra orbital segment of the nerve1.

In AION, the onset of symptoms is accompanied by optic disc edema revealed by fundoscopy with or without hemorrhage. Symptoms of AION rarely occur upon awakening. The onset of blindness is usually delayed from 48 h up to more than 1 week after surgery. Binocular involvement is more frequent than in other forms of ION. In PION, the optic disc appears normal at time of onset of symptoms. However, delayed disc edema may be observed as nerve ischemia spreads anteriorly. PION affects men (70%) more than woman and has been described even in young children (12 years old). In contrast to AION, with PION the majority of the patients report symptoms upon awakening (59%) with an additional 29% reporting symptoms within 24 h(1).

Most revised literature mentioned ischemic optic neuropathy occurred after spine surgery and mentioned the risk factors associated with it, in contrast there is a little mentioned about the optic neuropathy post cranial surgery as decompression for large lesions.

Case presentation

History

33 year old male sax playing musician with unremarkable past medical history, diagnosed recently with brain tumor after he started to experience bouts of severe headache and confusion for the past 2 months. He has been booked for elective craniotomy surgery, but he has been admitted as an emergency case after he presented with decreased level of consciousness and recurrent vomiting attacks. Patient resuscitated and prepared for urgent decompressive surgery.

Physical examination

Initial condition of patient when presented to the ER was unstable in his vitals and he has been managed accordingly with fluid, dexamethasone loading dose with pantodac, analgesia and his vitals were normalized.

On his neurological assessment on arrival, he was confused GCS:M5V2E2, bilaterally normal sized pupils with sluggish response to the light, no focal neurological deficit found. He had previous ophthalmological assessment showed normal result and rest of clinical assessment was unremarkable.

Imaging

MRI brain with contrast (figure 1) already done showed huge left fronto-parieto-temporal homogenously enhancing lesion with small foci of hypointensity seen centrally, the mass causing mass effect with midline shift. The lesion also investigated by MRA and MRV.

Surgery

Patient underwent left wide decompressive craniotomy with patient positioned supine and head was held in Mayfield head holder. Total excision of the lesion is done and patient recovered smoothly and admitted to the ICU with early postoperative was unremarkable during the first week.

Postoperative course

During the second week postoperative patient started to complain of blurred vision, visual assessment showed papilledema bilaterally and follow up CT brain (figure 2) was unremarkable for any residual lesion, significant bleed or feature of increased intracranial pressure. Histopathology result showed hemangiopericytoma.

Follow up

Patient subjected for serial therapeutic lumbar punctures (LP) and dexamethasone and on the week four he showed some improvement with light perception experienced but still blurred in his vision. his second ophthalmological assessment showed resolved papilledema but evident of optic atrophy noticed.

On week six patient vision deteriorated again and he lost the sense of light perception with last follow up CT brain was unremarkable (figure 3).

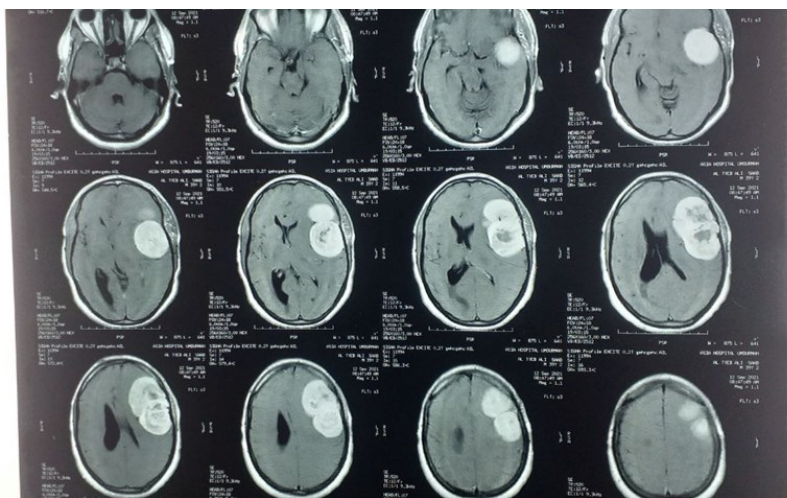


Figure 1: T1 weighted image with contrast MRI brain shows left fronto-parieto-temporal homogenously enhancing lesion with central hypointensity inconsistent with calcification, there is mass effect and midline shift.

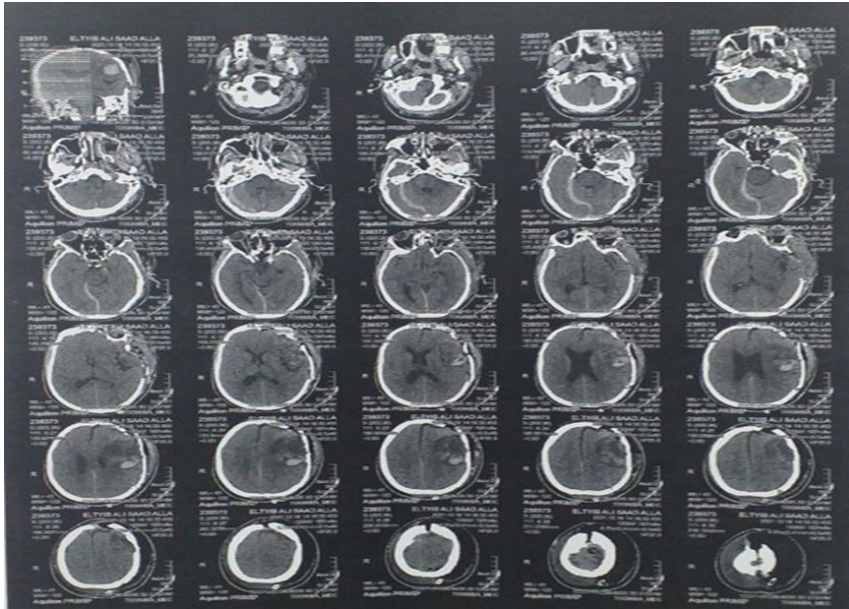


Figure 2: Plain follow up CT brain done in the second week shows total excision of the lesion and disappearance of the mass effect and the midline shift. There is small hematoma and focal edema at the surgical site as postoperative findings.

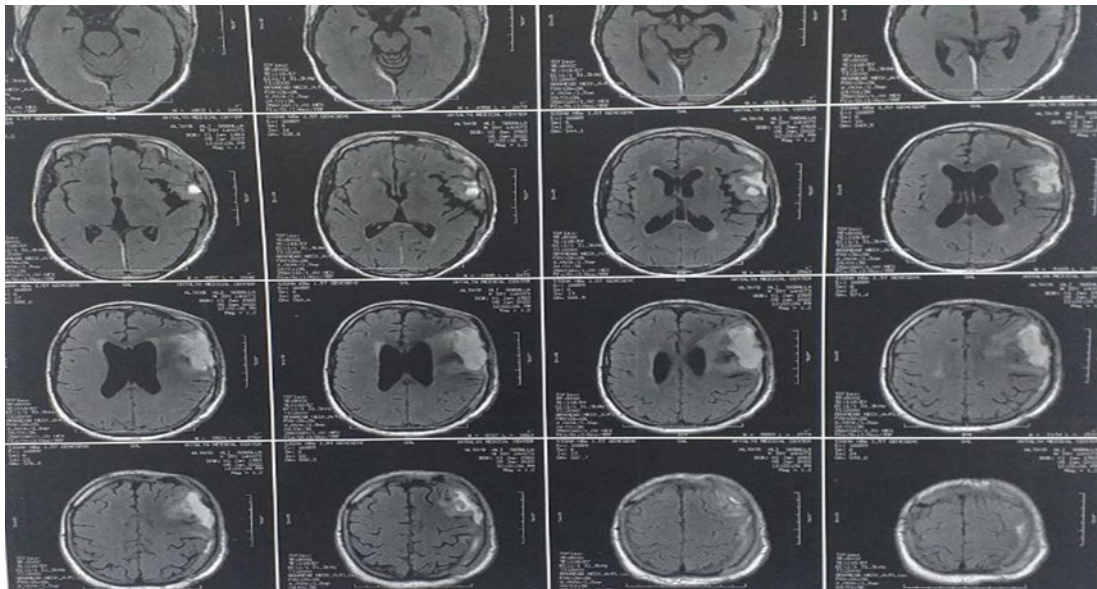


Figure 3: MRI brain axial cut, FLAIR sequence done on week 6 shows focal surgical site edema otherwise unremarkable for significant findings.

Discussion

Postcraniotomy or post decompressive blindness is uncommon complication seen in neurosurgery and is considered catastrophic one. It is commonly noticed after spinal surgery on prone position rather than cranial surgery on supine position. Its true incidence is not known and the pathogenesis is not fully understood(2), and risk factors remain speculative(1).so there are few cases reported in the literature. We present a case scenario of post craniotomy blindness in supine position seen as delayed complication and is considered as form of ischemic optic neuropathy. Male sex ,long surgery lasting more than 6hr and intraoperative hypotension are counted as possible risk factors (1).

On revising our case course of preoperative ,operative and postoperative period, we found that he had a significant blood loss during surgery with recorded reading of significant hypotension and long duration of surgery last more than 6hrs. Ischemic optic neuropathy is considered as the most common cause for such type of postoperative visual loss with two subtypes mentioned ,anterior and posterior, and anterior ischemic optic neuropathy presentation is delayed from 48 h up to more than 1 week after surgery accompanied by optic disc edema revealed by fundoscopy with or without hemorrhage(1). Our case showed delayed symptoms presented on the week two and accompanied with papilledema documented by fundoscopy assessment.

On revising literature there were five cases reported with visual loss postcraniotomy for different intracranial lesions with the visual loss seen either immediate upon awakening or as delayed one with papilledema found preoperatively. The pathogenesis in these cases was speculative(3). Our case showed fluctuating response to the proposed treatment modalities and patient last assessment showed static course of disease of blindness after short period of improvement noticed after the onset of treatment.in the literature All the therapeutic methods have failed to improve the patients visual outcome, such as high dose of acetazolamide, dexamethasone and serial lumbar puncture(2). And they suggested the preventive methods to be applied to high risk craniotomies These may include gradual lowering of ICP (e.g, piece-meal resection of large tumors when possible), careful monitoring of BP and VEP during surgery, maintaining blood pressure at normotensive status (not the preferred hypotensive status) and frequent eye checks to avoid external pressure on the eyes. We suggest using protective eye shields in all frontal craniotomies(2).The use of controlled hypotension may be contraindicated in this group of patients(3).

Conclusion

Ischemic optic neuropathy is not a common complication seen post craniotomy in supine position but rather in other surgeries like lumbar spinal surgery on prone position and cardiac surgery.it is still poorly understood and risk factors remain speculative. Given that there is no known treatment, increased understanding should help to prevent this post-operative complication and so, reporting in the literature is important to achieve that a thorough ophthalmological exam and consultation is advised for those patients who considered at high risk. also, From a medico-legal standpoint such complication should be discussed during counselling and consenting for the highly suspected cases.

Conflict of Interest

The authors declare no conflict of interest.

References

1. Goepfert CE, Ifune C, Tempelhoff R. Ischemic optic neuropathy : are we any further ? 2010;
2. Vahedi P, Meshkini A, Mohajernezhadfar Z, Tubbs RS. Post - craniotomy blindness in the supine position : Unlikely or ignored ? 2013;8(1):2-7.
3. Greenberg HS. Post-decompression optic neuropathy. 1985;63:196-9.

Citation: Eljili F, Hussein H, Mustafa M, Taha S, Altayeb S-“Post Craniotomy Blindness due to Optic Neuropathy: Case Report and Review of Literature”. *SVOA Neurology* 2022, 3:4, 150-153.

Copyright: © 2022 All rights reserved by Eljili F., et al. This is an open access article distributed under the Creative Commons Attribution License, which permits unrestricted use, distribution, and reproduction in any medium, provided the original work is properly cited.