

Surgical Removal of Odontogenic Keratocyst: Case Report

Karen Lorraine Batista Cunha¹, Daniel Nuciattelli Pinto de Mello², Estevam Rubens Utumi³,
Luís Augusto Collicchio⁴ and Irineu Gregnanin Pedron^{5*}

¹Undergraduate Student, Universidade Brasil, São Paulo, Brazil

²DDS, Birmingham, UK

³Preceptor and Oral and Maxillofacial Surgeon, Hospital Municipal Dr. Arthur Ribeiro de Saboya, São Paulo, Brazil

⁴Oral and Maxillofacial Surgeon and Major, Brazilian Air Force, Hospital de Força Aérea de São Paulo, São Paulo, Brazil

⁵Professor, Department of Periodontology, Implantology, Stomatology, Integrated Clinic, Laser and Therapeutics, Universidade Brasil, São Paulo, Brazil

Corresponding Author: Irineu Gregnanin Pedron, Professor, Department of Periodontology, Implantology, Stomatology, Integrated Clinic and Therapeutics, School of Dentistry, Universidade Brasil, São Paulo, Brazil, Tel: +55-11 2944-4067

Received: August 23, 2021 **Published:** August 30, 2021

Abstract:

Keratocyst is an odontogenic cyst that has growth potential, aggressiveness, histological behavior, and high recurrence rate, unlike radicular and dentigerous cysts. From this perspective, keratocyst was classified by World Health Organization as an odontogenic tumor in 2005, but portrayed as a cyst in the 2017 classification. Usually diagnosed on routine radiographic examinations, it is characterized by uni or multilocular radiolucent lesion. Frequently found in the posterior region and ramus of the mandible. The recommended treatment is surgical removal, by means of enucleation or marsupialization, bone resection, and the association between techniques. It has a high recurrence rate, usually related to the associated remaining tooth or to the surgical technique. The purpose of this article is to present a case of keratocyst, diagnosed accidentally in a routine radiographic exam, and treated by enucleation.

Keywords: odontogenic keratocyst; odontogenic cysts; odontogenic tumors; oral diagnosis; oral surgery.

Introduction

The odontogenic keratocyst is an intraosseous lesion, classified as an odontogenic cyst. It shows slow growth, although it is very aggressive and locally invasive. It can cause bone resorption and reach large proportions¹⁻¹².

Odontogenic keratocysts can be found in patients at several ages. However, approximately 60% of cases are diagnosed between the ages of 10 and 40. The mandible is affected in 60 to 80% of cases, with a marked tendency to involve the posterior region and the ascending ramus. In the maxilla (about 30%), the most affected site is the canine region^{1,3-5,7-9,11-14}. However, in the posterior maxilla, the lesion may involve the maxillary sinus, destroying its floor⁸. There is no predilection as to the gender of the patient^{9,11}.

Multiple keratocysts, associated with other manifestations, may indicate basal cell nevoid carcinoma syndrome^{5,9,10,13,16-18}. Imaging examinations should be employed to the exclusion of this condition.

The odontogenic keratocyst was originally classified as an odontogenic cyst. Later, in view of characteristics such as aggressiveness of the lesion, growth potential, histopathological and genetic aspects, the World Health Organization in 2005 classified it as a benign cystic neoplasm, and it was named keratocystic odontogenic tumor^{2,4,6,9,10,12,13,19,20}. In a new classification in 2017, the World Health Organization redefined the nomenclature to keratocyst^{1,3}.

The recommended treatment is surgical removal, by means of enucleation or marsupialization, bone resection or a combination of techniques^{1,9,13,17,20}. It has a high recurrence rate, ranging from 22 to 60%, generally associated with the remaining tooth^{2,4-12,20}.

The purpose of this article is to present a case of a keratocyst, diagnosed accidentally during a routine radiographic exam, and treated by enucleation.

Case Report

A Caucasian female patient, 51-years-old, came to a private clinic for routine dental treatment.

On routine radiographic examination (panoramic radiography), a unilocular, circumscribed, radiolucent lesion measuring approximately 40mm X 30mm, involving unerupted tooth 48 and advancing towards the mandibular ramus, with possible inferior deviation of the mandibular canal was observed (Figure 1). A computed tomography scan was requested.

Computed tomography revealed a hypodense image in the right mandibular ramus and a hyperdense image inside it, compatible, respectively, with the mandibular radiolucent lesion and involving the unerupted tooth 48 (Figure 2). The 3D reconstruction obtained by means of tomographic slices showed bone resorption of mandibular cortical on both the buccal and lingual sides of the mandible. The positioning of the unerupted tooth 48 and the inferior deviation of the mandibular canal were also demonstrated (Figure 3).

Clinically, no cortical bulging was observed (Figure 4). Among the diagnostic hypotheses, dentigerous cysts, ameloblastoma and odontogenic keratocyst were proposed.

Surgical removal was indicated to the patient, presenting all the care and risks inherent to the procedure. After consenting to the procedure, surgery was scheduled. No systemic diseases or conditions that would compromise the surgical procedure were reported.

Under local anesthesia, an incision was made on the right mandibular ramus up to the distal aspect of tooth 46 from the buccal aspect (Figure 5). An osteotomy was performed in the trigonoretromolar region until the exposure of the lesion (Figure 6), which was enucleated (Figure 7). The bone cavity was washed thoroughly and the region was sutured (Figure 8). Analgesic, anti-inflammatory and antibiotic drugs were prescribed to the patient.

The fragment of the lesion (Figure 9) was fixed in 10% formalin and sent to the Laboratory of Surgical Pathology of the School of Dentistry, University of São Paulo. Histopathological examination revealed stratified squamous epithelium with hyperchromatic cell nuclei arranged in palisade. The stroma showed a sparse inflammatory infiltrate composed of loose fibrous connective tissue. The diagnosis was odontogenic keratocyst.

The patient was evaluated after 15 days, and the remaining sutures were removed. No complaints and/or complications were reported. The patient has been followed up for 12 months with no signs of recurrence.

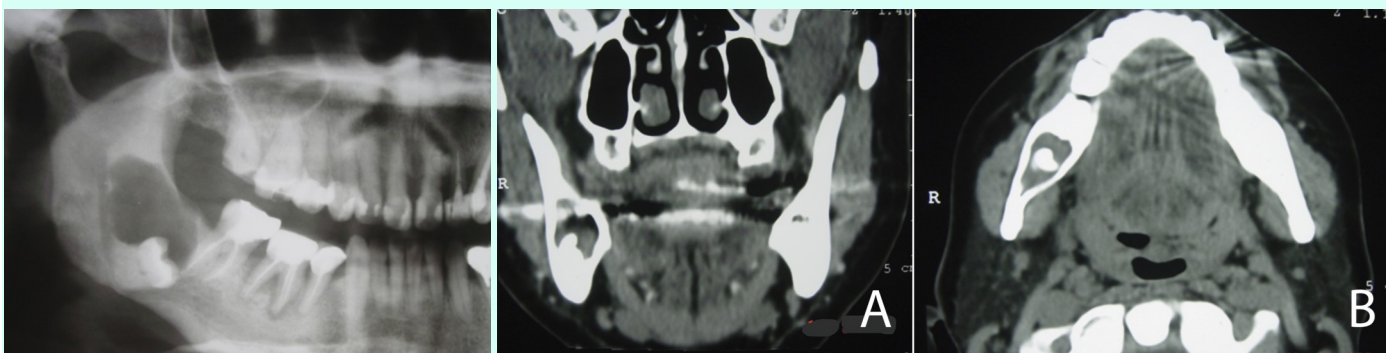


Figure 1: Routine radiographic examination (panoramic radiography) presenting radiolucent lesion involving unerupted tooth 48.

Figure 2: Computed tomography presenting hypodense image in the right mandibular ramus and a hyperdense image inside it. Coronal view (A). Axial view (B).

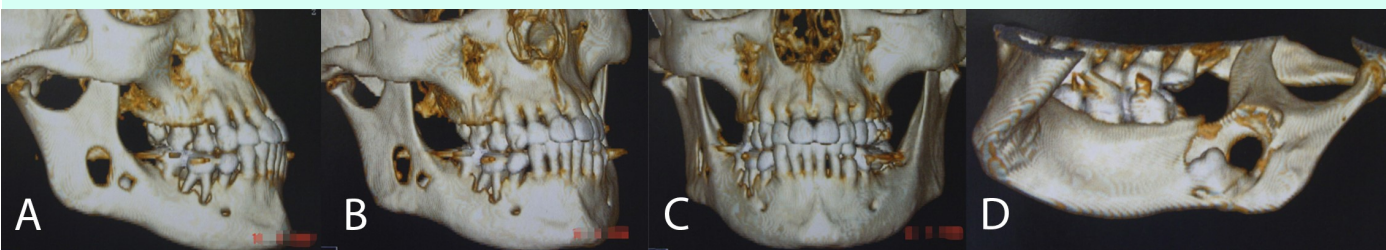

Figure 3: 3D reconstruction presenting bone resorption of mandibular cortical on both the buccal and lingual sides of the mandible. Right side view (A). Right half profile view (B). Front view (C). Lingual view (D).

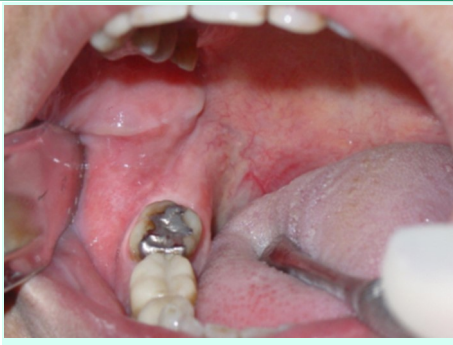

Figure 4: Initial clinical aspects: absence of abnormalities.

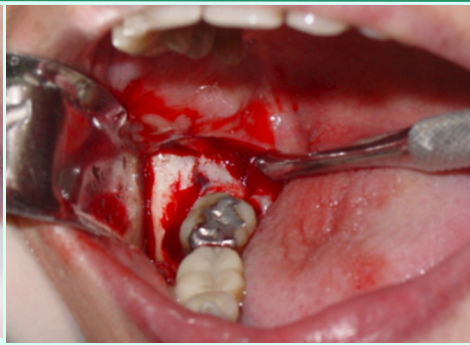


Figure 5: Incision on the right mandibular ramus up to the distal aspect of tooth 46 from the buccal aspect.

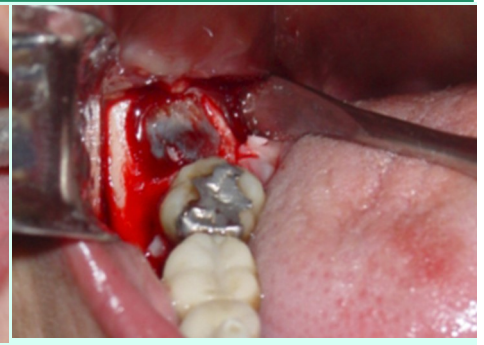

Figure 6: Osteotomy in the trigonoretromolar region until the exposure of the lesion.

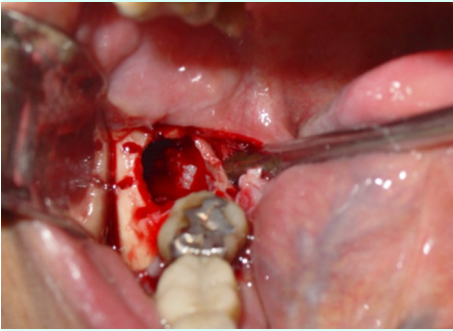


Figure 7: Enucleation of the lesion.

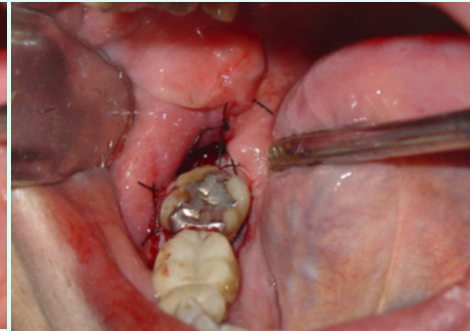


Figure 8: Region sutured.

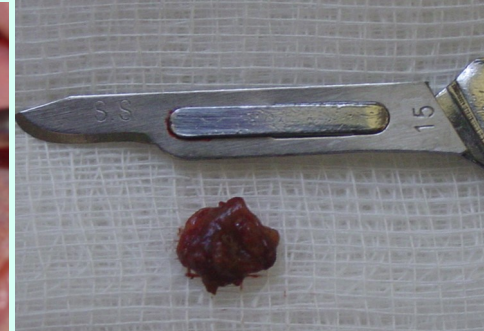

Figure 9: Fragment of the lesion.

Discussion

The odontogenic keratocyst was originally so named, being classified as an odontogenic cyst. However, as they are more aggressive lesions compared to the nature of radicular and dentigerous cysts, odontogenic keratocysts were classified as benign cystic neoplasms rather than cysts, taking on the denomination of keratocystic odontogenic tumor^{2,9,10,12,13,19}. This change in nomenclature (in 2005), was proposed by the World Health Organization^{2,12}. The marked expression of p53 protein (indicating cell proliferation with possible gene mutation), also supported this hypothesis. Later, deposits of perlecan - a protein observed in neoplastic conditions such as salivary gland tumors, odontogenic tumors, and oral carcinoma in situ - also supported the neoplastic nature of the lesion and this new nomenclature²⁰. Additionally, the intense expression of heparanase in keratocystic odontogenic tumor has been found to correlate with the neoplastic properties of the tumor, especially when associated with the basal cell nevus carcinoma syndrome. The increased level of heparanase enzyme in tumors promotes invasion and metastasis¹⁰. Currently, keratocyst is classified as odontogenic cyst by the latest World Health Organization classification in 2017^{1,13}.

It is often diagnosed incidentally on routine radiographic examinations⁶. However, a clinical finding that arouses interest is cortical bone expansion^{1,9,13} or bone resorption^{1,3,11,13}. Radiographically, the osteolytic lesion is characterized by a unilocular radiolucent image, which can also be multilocular, but less frequently^{4,13}. It is usually well delimited and surrounded by bone sclerosis⁷.

It is lined by uniform stratified pavementous epithelium, mostly parakeratinized, and a basal layer composed of columnar or cuboidal cells arranged in a palisade^{1,2,7,13,18}.

The clinical, radiographic and trans-surgical features of keratocyst commonly lead to the diagnostic hypothesis of ameloblastoma (when the pattern is multilocular) and dentigerous cyst (unilocular), when associated with the impacted tooth^{1,13}. Additionally, adenomatoid odontogenic tumor, calcifying odontogenic cyst and ameloblastic fibroma are included in the differential diagnosis³.

The recommended treatment is surgical removal, by means of enucleation or marsupialization, and the association between techniques^{1-3,9,13,18,20}. When necessary, the most aggressive treatment is indicated, proposing resection or enucleation complemented with Carnoy's solution with or without peripheral osteotomy. It has been established that the worse the aggressive nature of the keratocyst, the more invasive the treatment will be^{1-3,12,13,18}. Future therapeutic modalities may be based on molecular treatments, favoring the reduction or elimination of the need for aggressive surgical maneuvers¹².

Keratocyst has a high recurrence rate, ranging from 22 to 60%, usually associated with the remaining tooth^{2-12,18}. It differs from other odontogenic cysts, and its histological characteristics, confirmed in histopathological examination, are directly linked to the rate of recurrence and aggressiveness¹². Recurrence can occur even 10 years after surgery⁴. From this perspective, prolonged clinical-radiographic follow-up of the patient after removal of the keratocyst is recommended³. Recurrence also depends on the surgical modality. Marsupialization alone or associated with subsequent enucleation can reduce the recurrence rate compared to enucleation alone^{1-3,9,18,20}. The more aggressive the treatment, the lower the recurrence rate. The more aggressive treatment (bone resection) resulted in less recurrence compared to simple enucleation or marsupialization¹². It was also cited that the recurrence of the lesion is not only related to the surgical technique, but also to the multifocal nature of the lesion⁶. Early diagnosis and treatment of keratocyst also decreases the recurrence rate¹¹.

Conclusion

Since 2017, odontogenic keratocyst is considered a cystic lesion. In 2005, it was classified by the World Health Organization as an odontogenic tumor, given its aggressiveness, growth potential, neoplastic nature, and high recurrence rate. Keratocysts grow slowly, but are aggressive and can reach large dimensions. Treatment is surgical, with variations in techniques (enucleation, marsupialization, or resection). The more aggressive the lesion, the more radical the treatment, while reducing the possibility of recurrence. Marsupialization can promote reduction in the size of the lesion, preparing it for future enucleation. When performed early, the diagnosis and adequate treatment of odontogenic keratocyst can favor the prognosis, also reducing the possibility of recurrence.

References

- Borrás-Ferreres J, Sánchez-Torres A, Alberdi-Navarro J, Aguirre-Urizar JM, Mosqueda-Taylor A, Gay-Escoda C. Therapeutic management of the odontogenic keratocyst. An energetic approach with a conservative perspective and review of the current therapeutic options. *J Clin Exp Dent*. 2020;12(8):e794-9.
- Farshidfar N, Agharokh M, Daneste H. Eruption of permanent first premolar associated with a mandibular keratocystic odontogenic tumor after marsupialization in a 9-year boy: A case report with 2 years of follow-up. *J Dent (Shiraz)* 2021;22(2):144-148.
- Vallejo-Rosero KA, Camolesi GV, de Sá PLD, Bernaola-Paredes WE. Conservative management of odontogenic keratocyst with long-term 5-year follow-up: Case report and literature review. *Int J Surg Case Rep* 2020;66:8-15.
- Waldron CA. Cistos e tumores odontogênicos. In: Neville BW, Damm DD, Allen CM, Bouquot JE. *Patologia oral e maxilofacial*. Rio de Janeiro: Guanabara Koogan; 1998. p.485-90.
- Ali M, Baughman RA. Maxillary odontogenic keratocyst: a common and serious clinical misdiagnosis. *J Am Dent Assoc* 2003;134(7): 877-83.
- Boyne PJ, Hou D, Moretta C, Pritchard T. The multifocal nature of odontogenic keratocysts. *J Calif Dent Assoc*. 2005;33(12): 961-5.
- Chirapathomsakul D, Sastravaha P, Jansisyanont P. A review of odontogenic keratocysts and the behaviour of recurrences. *Oral Surg Oral Med Oral Pathol Oral Radiol Endod*. 2006;101(1):5-9.
- Vencio EF, Mota A, de Melo Pinho C, Dias Filho AA. Odontogenic keratocyst in maxillary sinus with invasive behaviour. *J Oral Pathol Med*. 2006;35(4):249-51.
- Habibi A, Saghravanian N, Habibi M, Mellati E, Habibi M. Keratocystic odontogenic tumor: a 10-year retrospective study of 83 cases in a Iranian population. *J Oral Sci*. 2007;49(3):229-35.
- Katase N, Nagatsuka H, Tsujigiwa H, Gunduz M, Tamamura R, Pwint HP et al. Analysis of the neoplastic nature and biological potential of sporadic and nevoid basal cell carcinoma syndrome-associated keratocystic odontogenic tumor. *J Oral Pathol Med*. 2007;36(9):550-4.
- Mozaffari E, Marmor DS, Alawi F. Odontogenic keratocyst with a misleading clinical e radiologic appearance. *Quintessence Int*. 2007;38(10):837-41.
- Madras J, Lapointe H. Keratocystic odontogenic tumour: reclassification of the odontogenic keratocyst from cyst to tumour. *J Can Dent Assoc*. 2008;74(2):165-h.
- Santosh ABR. Odontogenic cysts. *Dent Clin North Am* 2020;64(1):105-119.
- Koseoglu BG, Atalay B, Erdem MA. Odontogenic cysts: a clinical study of 90 cases. *J Oral Sci*. 2004;46(4):253-7.
- Ramaglia L, Morgese F, Pighetti M, Saviano R. Odontogenic keratocyst and uterus bicornis in nevoid basal cell carcinoma syndrome: case report and literature review. *Oral Surg Oral Med Oral Pathol Oral Radiol Endod*. 2006;102(2):217-9.

16. Auluck A, Suhas S, Pai KM. Multiple odontogenic keratocysts: report of a case. *J Can Dent Assoc.* 2006;72(7): 651-6.
17. França GM, Silva LBA, Mafra RP, Silva WR, Lima KC, Galvão HC. Recurrence-free survival and prognostic factors of odontogenic keratocyst: a single-center retrospective cohort. *Eur Arch Otorhinolaryngol* 2021;278(4):1223-1231.
18. Heikinheimo K, Jee KJ, Morgan PR, Nagy B, Knuutila S, Leivo I. Genetic changes in sporadic keratocystic odontogenic tumors (odontogenic keratocysts). *J Dent Res.* 2007;86(6):544-9.
19. Tsuneki M, Cheng J, Maruyama S, Ida-Yonemochi H, Nakajima M, Saku T. Perlecan-rich epithelial linings as a background of proliferative potentials of keratocystic odontogenic tumor. *J Oral Pathol Med.* 2008;37(5):287-93.
20. Slusarenko da Silva Y, Stoelinga PJW, Naclério-Homem MG. Recurrence of nonsyndromic odontogenic keratocyst after marsupialization and delayed enucleation vs. Enucleation alone: a systematic review and meta-analysis. *Oral Maxillofac Surg* 2019;23(1):1-11.

Citation: Cunha KLB, de Mello DNP, Utumi ER, Collicchio LA, Pedron IG. "Surgical Removal of Odontogenic Keratocyst: Case Report". *SVOA Dentistry* 2:5 (2021) Pages 227-231.

Copyright: © 2021 All rights reserved by Pedron IG., et al. This is an open access article distributed under the Creative Commons Attribution License, which permits unrestricted use, distribution, and reproduction in any medium, provided the original work is properly cited.